

The eighth in a series of articles on diagnosing and managing genitourinary infections

8. Genital lumps and bumps: what is normal?

COLM O'MAHONY

When patients present with genital 'lesions', it is important to distinguish between normal anatomical variants, which usually require only reassurance, and other similar-appearing conditions such as genital warts. Dr O'Mahony provides an illustrated account of some common normal genital lumps and bumps.

Dr C. O'Mahony, MD, FRCP, DIPVen, Consultant Physician (Genitourinary Medicine), Countess of Chester Hospital, Chester.

When patients notice changes in the appearance of their genitals, colour variations, or the presence of lumps and bumps, it is not easy for them to know whether these are normal variants or a more serious condition that requires a visit to the GP or genitourinary medicine clinic. Indeed, in a few cases, even experienced doctors and nurses may be uncertain whether pearly penile papules or vestibular papillae are really early genital warts. Often, patients simply require reassurance that their 'lesions' are just a normal variation or a harmless anomaly of no significance.

Pearly penile papules

Pearly penile papules are common; there may be only a few lesions on the penis, or they may be abundant (Figure 1). These are normal glands, typically located around the corona of the glans penis. They seem to develop more prominently during the teenage years and can be alarming. Although they will never disappear completely, they do become less noticeable with increasing age. Patients often request treatment for cosmetic reasons, but this is not recommended.

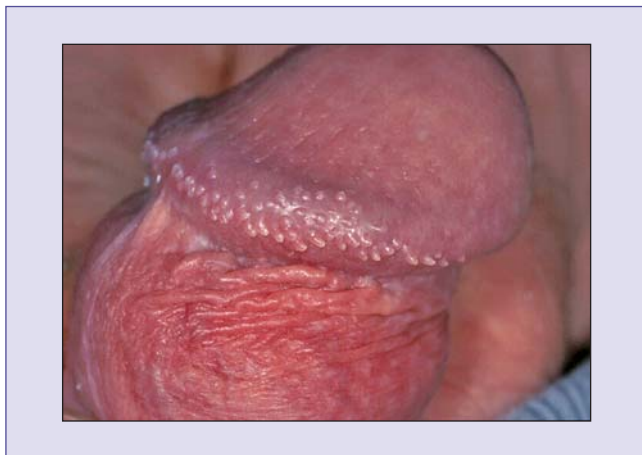


Figure 1. Pearly penile papules on the coronal sulcus.

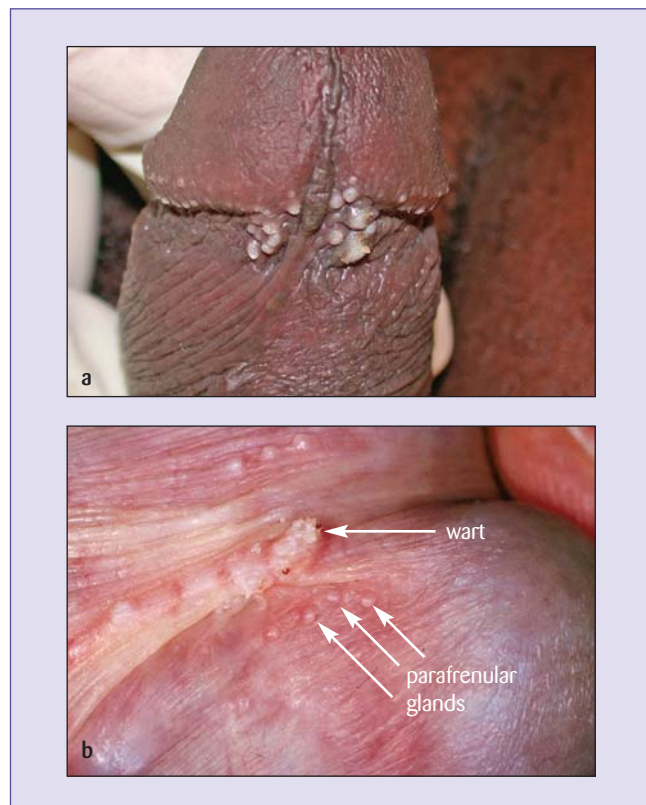


Figure 2. (a) Parafrenular glands on either side of the frenulum. (b) Symmetrically placed parafrenular glands with a wart on the frenulum. Note the smooth surface of the parafrenular glands compared with the rough surface of the wart.

Parafrenular glands

These are normal glands that appear on either side of the frenulum. Occasionally, just three or four glands are lined up symmetrically. More often, however, the glands are scattered, and may look like genital warts to the inexperienced eye. In darker-coloured skin they may be even more dramatic (Figure 2a). The glands are usually small and smooth in comparison to warts, which have a rough surface (Figure 2b). When both parafrenular glands and warts are present,

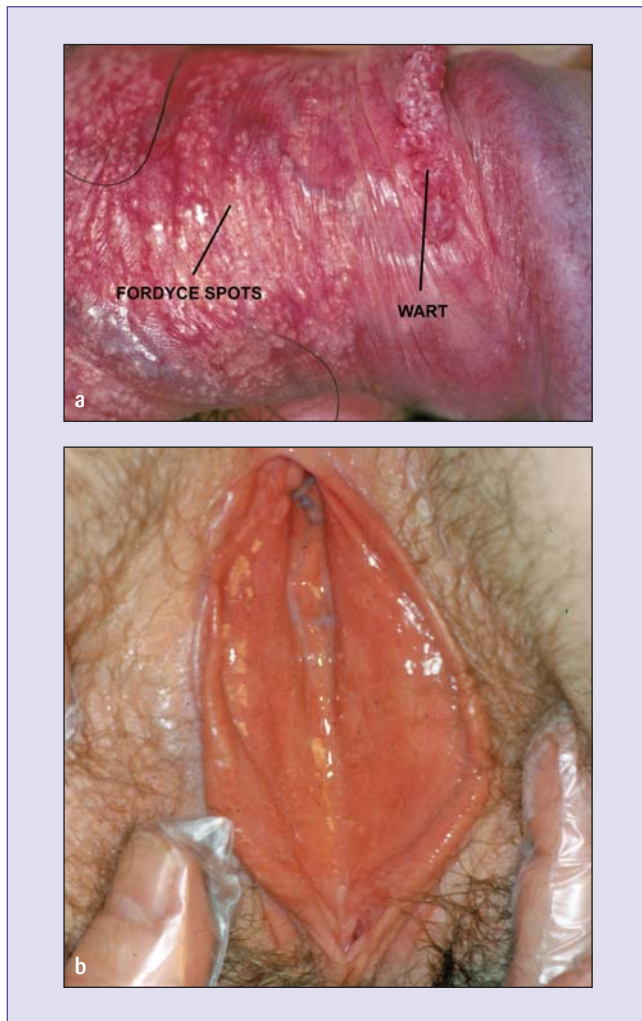


Figure 3. (a) Fordyce spots and a wart on the penis. (b) A few small, well-defined patches of Fordyce spots in the vestibular area of the vulva.

it is important that the patient can distinguish between them. It should be explained that the warts can be successfully treated at home with podophylotoxin or imiquimod, but the para-frenular glands will not respond to treatment. The diagnosis and treatment of genital warts was discussed in a previous article in this series.¹

Fordyce spots

These small glands may be scattered in clusters along the reflex prepuce, on the shaft of the penis and in the vestibular area of the vulva. In some patients, they may be extensive and quite dramatic, especially when the skin is stretched. Figure 3a shows many Fordyce spots on the penile skin, with a wart for comparison. There may be just one or two patches of glands (Figure 3b), or they may be more confluent.

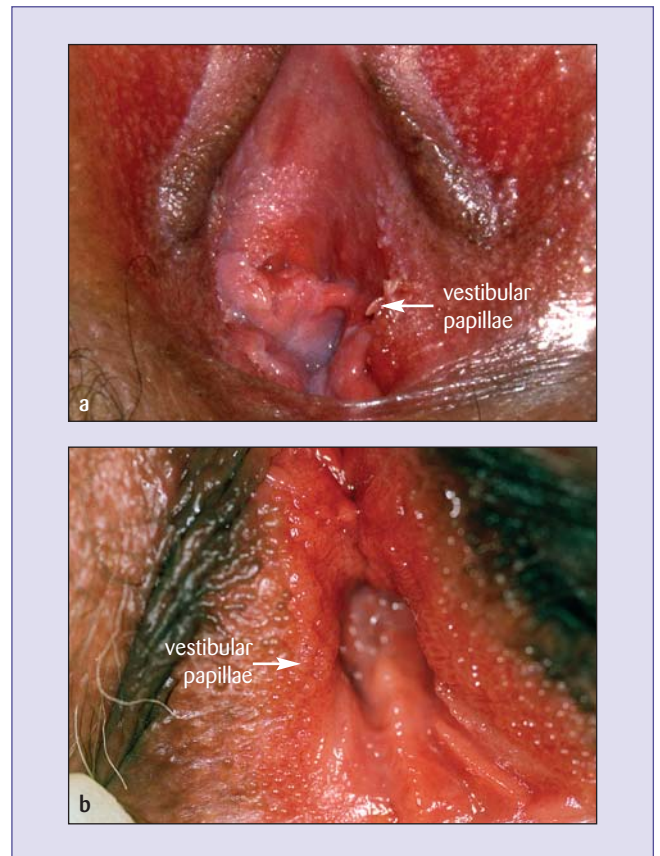


Figure 4. (a) Frond-like vestibular papillae, (b) Small vestibular papillae can easily be confused with warts, but usually appear in a symmetrical pattern.

Vestibular papillae

Although rare, these small, frond-like glands can be quite confusing if they are extensive (Figure 4a). They often appear as small, smooth projections that resemble cobblestones. In some patients, it is almost impossible to distinguish between early genital warts and vestibular papillae

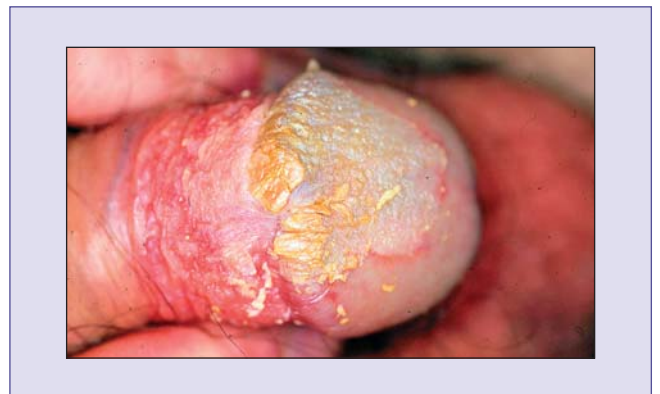

Figure 5. Smegma in a young man who had never withdrawn his foreskin.

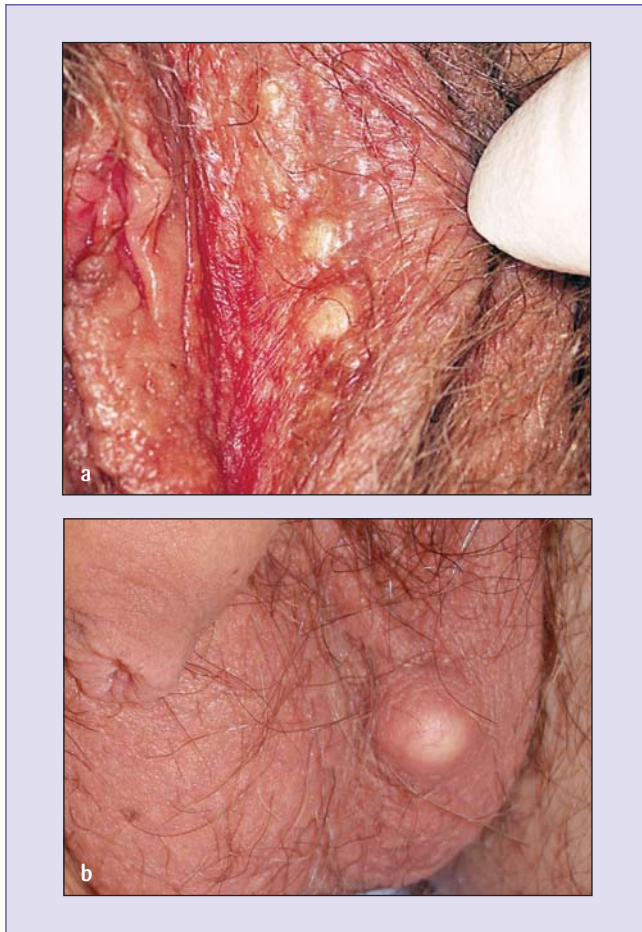

Figure 6. Sebaceous cysts: (a) small labial and (b) large scrotal cysts.

(Figure 4b). Unlike warts, vestibular papillae are usually located in a symmetrical pattern. However, if uncertain, it is best to review the patient after a month or two.

Smegma

Young men sometimes present with an apparent inability to retract the foreskin, and pain and discomfort in the penis. This can be a result of never having pulled back the foreskin to wash out the debris that accumulates underneath (Figure 5). The young man shown here washed his penis in warm, soapy water three times a day for two weeks, after which the skin was in pristine condition.

Sebaceous cysts

Sebaceous cysts are very common in the genital area. They are painless, but may grow quite fast and can be alarming. They may be relatively discreet (Figure 6a) or very prominent, particularly on the scrotum (Figure 6b), and many patients request surgical excision for cosmetic reasons. However, they are harmless, and should be left alone.

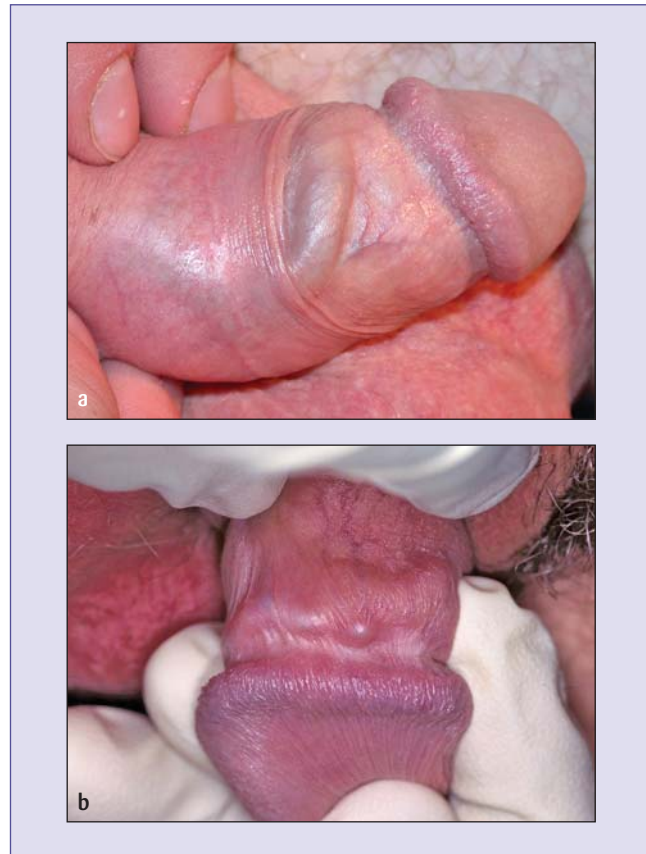


Figure 7. Lymphocoele: (a) smooth, cord-like swelling and (b) with fibrosis and solid lumps.

Lymphocoele

This is a cord-like swelling that develops behind the coronal sulcus, caused by a lymph channel that has become solidified. The swelling may be smooth (Figure 7a) or may develop knobby lumps (Figure 7b), leading to concern about the possibility of cancer. The swelling can occur spontaneously or after vigorous sex or masturbation. If it is painful, anti-inflammatory medication (ibuprofen 400mg three times daily with food) may be necessary. The cord-like swelling gradually disappears and is of no consequence. Patients should be reassured that it is not a clot.

Conclusion

Fear and embarrassment about perceived genital anomalies are relatively common. Reassurance, delivered with authority and confidence, and if possible backed up by showing the patient illustrations of similar conditions, is often all that is required.

Reference

1. Gilson R. Sorting out genital warts. *Trends Urol Gynaecol Sex Health* 2005; **10**(4): 26-30.